

# Outcomes of Micropulse Transscleral Cyclophotocoagulation in Uncontrolled Glaucoma Patients

Karen Zaarour, MD,\*†‡ Youssef Abdelmassih, MD,\*†‡ Nicolas Arej, MD,\*†  
Georges Cherfan, MD,† Karim F. Tomey, MD,†§ and Ziad Khoueir, MD\*†

**Purpose:** This study aimed at evaluating the intermediate-term efficacy and safety of micropulse transscleral cyclophotocoagulation (MP-TSCPC) in cases of uncontrolled glaucoma.

**Methods:** Patients with moderate to advanced glaucoma and uncontrolled intraocular pressure (IOP) despite maximally tolerable antiglaucoma medications were selected to undergo MP-TSCPC using the MP3 handpiece with the Iridex Cyclo G6 (IRIDEX Laser Systems). Follow-up examinations took place on a regular basis until 15 months postoperatively.

**Results:** Seventy-five eyes of 69 patients (53.6% male patients) were included. Mean age was  $55.5 \pm 22.9$  years. Primary open-angle glaucoma was the most common diagnosis. Corrected distance visual acuity at baseline ranged between 0 and 2.1 logMAR. Mean prelaser IOP was  $26.0 \pm 7.91$  mm Hg. This was reduced significantly to  $13.8 \pm 5.6$  mm Hg (44.0% reduction,  $P < 0.001$ ) at week 1, and to  $18.0 \pm 7.7$ ,  $18.4 \pm 7.1$ ,  $16.7 \pm 6.2$ ,  $15.1 \pm 4.1$ ,  $15.7 \pm 5.32$ , and  $14.8 \pm 5.50$  mm Hg at months 1, 3, 6, 9, 12, and 15, respectively. The mean number of antiglaucoma drops decreased significantly up to 12 months of follow-up ( $P = 0.008$ ) and that of oral acetazolamide tablets decreased significantly up to 15 months ( $P < 0.001$ ). The success rate decreased progressively with time, reaching 81.4% at 6 months and 73.3% at 1 year. No major postoperative complications were encountered, and no eye lost vision completely.

**Conclusions:** MP-TSCPC is an efficient noninvasive glaucoma treatment that achieves sustained IOP reduction and reduced need for ocular antihypertensive medications for up to 15 months. The optimal laser parameters to achieve the best success rate with the least side effects still need to be determined.

**Key Words:** glaucoma, intraocular pressure, micropulse transscleral cyclophotocoagulation

(*J Glaucoma* 2019;28:270–275)

Glaucoma is the leading cause of irreversible blindness worldwide, with >70 million people affected and ~10% becoming legally blind during their lifetime.<sup>1</sup> According to current evidence, glaucoma is defined as a group of optic

neuropathies manifesting as progressive degeneration of the retinal ganglion cell layer, with consequent optic disc remodeling and cupping, and ultimately irreversible visual field loss.<sup>2</sup> Treatment aims at lowering intraocular pressure (IOP), either by reducing aqueous humor production or by increasing its outflow through the trabecular or uveoscleral routes, or both. Treatment options include topical medications, laser therapies, minimally invasive glaucoma surgery, incisional surgeries, glaucoma drainage implants, and cycloablative procedures.<sup>2</sup>

Transscleral cyclophotocoagulation (TSCPC) is a cyclo-destructive procedure designed to target the melanin in the pigmented ciliary body epithelium, thereby decreasing the rate of aqueous humor production. Many studies have confirmed the IOP-lowering ability of TSCPC,<sup>3–5</sup> whereas others reported the risk of developing serious complications with this procedure, such as persistent ocular inflammation, vision loss, hypotony, phthisis bulbi, and rarely sympathetic ophthalmia.<sup>6–9</sup> Therefore, TSCPC, which conventionally uses the continuous-wave diode laser, has been reserved for the treatment of refractory glaucoma or palliation of painful eyes that have poor visual prognosis.<sup>10</sup> The more recently introduced diode laser micropulse TSCPC (MP-TSCPC; Iridex Cyclo G6 Laser Systems, Mountain View, CA) is now being used to treat glaucoma by delivering repetitive short pulses of 810 nm infrared diode laser radiation.<sup>11–15</sup> With its “on” and “off” cycling mode, it allows energy to reach the coagulative threshold in the targeted pigmented tissues with minimal collateral disruption of the nonpigmented epithelium, the ciliary body stroma, and adjacent tissue.<sup>11,12</sup> In fact, no major anterior segment anatomic modifications on either ultrasound biomicroscopy or anterior segment optic coherence tomography have been demonstrated following the MP-TSCPC procedure.<sup>16</sup> This is in contrast to the traditionally used continuous-wave TSCPC, wherein thermal tissue damage has been confirmed histologically.<sup>17,18</sup>

Only a few studies have reported promising results with this novel treatment, making MP-TSCPC a potential treatment option among glaucoma specialists. However, those studies used a wide range of treatment parameters over variable follow-up periods.<sup>11–15,19,20</sup>

In our perspective, consecutive case series, we aim at evaluating the intermediate-term efficacy and safety of a standardized fixed MP-TSCPC protocol in the treatment of medically uncontrolled glaucoma, irrespective of visual acuity and previous surgical therapy. To our knowledge, this is the largest cohort of patients having undergone MP-TSCPC using a standardized protocol with fixed parameters.

## METHODS

This is a prospective, noncomparative interventional case series of patients with refractory glaucoma treated with MP-TSCPC at the Beirut Eye and ENT Specialist Hospital (BESH), Lebanon, between May 2016 and July 2018. Approval was obtained from the BESH Institutional Review Board, and the

Received for publication May 13, 2018; accepted December 4, 2018.  
From the \*Saint-Joseph University, Faculty of Medicine; †Beirut Eye and ENT Specialist Hospital, Beirut; ‡Lebanese American University, Gilbert and Rose-Mary Chagoury School of Medicine, Byblos, Lebanon; and §Fondation Ophthalmologique Adolphe de Rothschild, Paris, France.

Disclosure: The authors declare no conflict of interest.  
Reprints: Ziad Khoueir, MD, Beirut Eye and ENT Specialist Hospital, Al-Mathaf Square, P.O. Box 116-5311, Beirut, Lebanon (e-mail: ziad@khoueir.com).

Copyright © 2019 The Author(s). Published by Wolters Kluwer Health, Inc. This is an open-access article distributed under the terms of the Creative Commons Attribution-Non Commercial-No Derivatives License 4.0 (CCBY-NC-ND), where it is permissible to download and share the work provided it is properly cited. The work cannot be changed in any way or used commercially without permission from the journal.

DOI: 10.1097/IJG.0000000000001174

study followed the principles of the Declaration of Helsinki. Each patient signed an informed consent before enrollment.

Patients who were selected to undergo the procedure were all diagnosed with moderate to advanced glaucoma. All had uncontrolled IOP >21 mm Hg despite maximally tolerated topical and systemic antiglaucoma medications, and previous surgical therapy if any. The choice between MP-TSCPC and other surgeries such as filtering procedure or tube shunt was left to the discretion of each surgeon on the basis of the risk of intraoperative and postoperative complications of the surgical management and with consideration for the patient's preference. A more conservative approach was chosen in eyes with high-risk surgery or where others surgeries had failed.<sup>12</sup> Patients undergoing any intraocular surgery within 2 months of enrollment, having any sign of ocular infection or inflammation, being noncompliant to treatment or unable to keep their follow-up appointments, and patients having an extended scleral thinning for > 1 clock hour were excluded from the study.

All procedures were performed in the operating room by 1 of 2 glaucoma specialists (K.F.T. or Z.K.). Before the session, all patients received a peribulbar or retrobulbar anesthesia with a 1:1 mixture of bupivacaine 0.5% and lidocaine 2%, whereas intravenous sedation and analgesia were administered according to the patient's need. The MP3 handpiece was used with the Iridex Cyclo G6 (IRIDEX Laser Systems), with a standardized preset power of 2000 mW and a duty cycle (proportion of each cycle during which the laser is on) of 31.33% (micropulse "on" 0.5 ms, micropulse "off" 1.1 ms) for all patients. The laser probe's fiber-optic tip was applied with steady pressure in a continuous sliding arc (painting) motion over 360 degrees for 180 seconds on all patients. The tip is designed in a way to fit and adhere to the ocular globe at 3 mm posterior to the limbus.<sup>12</sup> Care was taken to avoid the 3 o'clock and 9 o'clock meridians, areas of scleral thinning, sites of failed filtering blebs, and glaucoma drainage devices.

The eye was patched for 24 hours; thereafter, patients were started on topical tobramycin 0.3% combined with dexamethasone 0.1% (Tobradex; Alcon, Fort Worth) tapered off over 4 weeks, ketorolac tromethamine 0.45% (Acuvail; Allergan Inc., Irvine, CA) for 1 week, and preservative-free lubricating drops. Patients were informed not to stop any prior antiglaucoma medication unless instructed otherwise.

Baseline parameters including age, sex, glaucoma type, previous glaucoma surgery, number of glaucoma medications (drops and tablets), preoperative IOP in millimeters of mercury (obtained by calculating the mean of 2 measurements taken 5 minutes apart by Goldmann applanation tonometry or by iCare rebound tonometry when Goldmann applanation tonometry was not possible), and corrected distance visual acuity (CDVA) were recorded.

Follow-up examinations were performed at 1 day, 1 week, 1 month, 3 months, 6 months, 9 months, 12 months, and 15 months postoperatively. At each visit, the following variables were recorded: CDVA, IOP, and number of antiglaucoma medications needed to control the IOP. Simultaneously, a complete slit-lamp examination was conducted to record any complication: anterior chamber (AC) reaction (grading of cells and flare within a slit-lamp beam window of 1 mm×1 mm based on the Standardization of Uveitis Nomenclature Working Group's consensus),<sup>21</sup> corneal edema, persistent ocular hypotony (IOP < 6 mm Hg) on 2 consecutive follow-ups, choroidal detachment, phthisis bulbi, sympathetic ophthalmia, cystoid macular edema, or any other abnormal ocular finding. A two-line (logMAR scale) reduction in CDVA in comparison with baseline or a

loss of light perception were also noted and considered as complications.

Success was defined as an IOP between 6 and 21 mm Hg or an IOP reduction of >20% compared with baseline, achieved with or without IOP-lowering agents.

Medical treatment was adjusted for each patient on every visit and reduced when possible in a stepwise approach, starting with oral acetazolamide. A retreatment session was contemplated no sooner than 3 months after the initial treatment for patients who failed to respond on 2 consecutive follow-ups. The decision to switch to a penetrating glaucoma surgery was left to the surgeon's discretion and taken on a case-by-case basis. Patients needing retreatment or invasive surgeries were considered as failure in the remaining follow-up visits.

The SPSS program, version 22.0 (SPSS Inc., Chicago, IL), was used for data management and analysis. Descriptive statistics were reported as mean ± SD for continuous variables and as a percentage for categorical variables. Preoperative and postoperative data were compared using a dependent *t* test for equality of means. A *P*-value <0.05 was considered to be statistically significant.

## RESULTS

A total of 69 patients (75 eyes) underwent the procedure. Their mean age was 55.5 ± 22.9 years (range: 7 to 90), and 53.6% were men. Primary open-angle glaucoma was the most common diagnosis, found in 34.7% (n=26) of eyes. Fifty-six percent of eyes (n=42) had undergone previous glaucoma intervention, with Ahmed glaucoma valve implantation (26.7%, n=20) and trabeculectomy (18.7%, n=14) being the most commonly performed procedures. Mean CDVA at baseline was 0.86 ± 0.66 logMAR (range: 0 to 2.1; converted from Snellen chart). See Table 1 for patients' demographic and

**TABLE 1.** Patients' Characteristics at Baseline

No. patients (number of eyes)	69 patients (75 eyes)
Age [mean (± SD)] (y)	55.51 (± 22.92)
Sex [n (%)]	
Male	37 patients (53.6)
Female	32 patients (46.4)
Prior glaucoma surgery [n (%)]	42 eyes (56)
Family history of glaucoma [n (%)]	4 patients (5.80)
Eyes needing retreatment [n (%)]	6 eyes (8.0)
Etiology/diagnosis [n (%)]	
Primary open-angle glaucoma	26 eyes (34.7)
Secondary glaucoma	10 eyes (13.3)
After penetrating keratoplasty	7 eyes (9.4)
Chronic angle-closure glaucoma	6 eyes (8.0)
Congenital glaucoma	5 eyes (6.7)
Unknown	5 eyes (6.7)
Neovascular glaucoma	4 eyes (5.3)
Mixed mechanism glaucoma	4 eyes (5.3)
Pseudoexfoliative glaucoma	3 eyes (4.0)
Aphakia	2 eyes (2.7)
Aniridia	1 eye (1.3)
Fuchs heterochromic iridocyclitis	1 eye (1.3)
Juvenile glaucoma	1 eye (1.3)
Prior glaucoma interventions [n (%)]	
Ahmed glaucoma valve	20 eyes (26.7)
Trabeculectomy	14 eyes (18.7)
Diode laser cyclophotocoagulation	6 eyes (8.0)
Laser peripheral iridotomy	6 eyes (8.0)
Selective laser trabeculoplasty	3 eyes (4.0)

This table represents baseline characteristics of included patients and eyes.

baseline characteristics. At the 1-year follow-up, 13 patients (15 eyes) were lost to follow-up.

The mean follow-up period was 13.2 ± 3.04 months (range: 1 to 15), with all eyes reaching the 1-month, 72 (96.0%) the 3-month, 70 (93.3%) the 6-month, 65 (86.7%) the 9-month, 60 (80.0%) the 12-month, and 47 (62.7%) the 15-month follow-up.

**Effect of MP-TSCPC on IOP**

Mean IOP at presentation was 26.0 ± 7.9 (range: 15 to 50). It was reduced significantly to 13.8 ± 5.6 mm Hg (a 44.0% reduction) at the 1 week, to 18.0 ± 7.7 mm Hg (a 25.5% reduction) at the 1-month, 18.4 ± 7.1 mm Hg (a 23.9% reduction) at the 3-month, 16.7 ± 6.2 mm Hg (a 29.3% reduction) at the 6-month, 15.1 ± 4.1 mm Hg (a 36.5% reduction) at the 9-month, 15.7 ± 5.3 mm Hg (a 31.8% reduction) at the 12-month, and 14.8 ± 5.5 mm Hg (a 35.4% reduction) at the 15-month follow-up (P < 0.001 at all the follow-up visits). The percentage of eyes that successfully achieved a decrease of at least 20% of their baseline IOP decreased progressively from 86.7% at 1 month to 67.1% at 6 months, and 56.7% in 1 year. Table 2 shows the postoperative outcomes at different follow-up dates. Figure 1 illustrates the mean IOP progression over the entire follow-up period and Figure 2 IOP reduction for each eye at the 3, 6, 9, and 12-month follow-up.

**Effect of MP-TSCPC on Antiglaucoma Drugs**

On the one hand, the number of topical glaucoma medications used decreased significantly after the procedure up to the 12-month follow-up (P = 0.008) (Table 2). On the other hand, the reduction in the number of oral acetazolamide tablets was more pronounced, with the decrease remaining significant until the 15-month follow-up (P < 0.001). In fact, of the 57.3% (43/75) of patients needing oral acetazolamide at baseline, this number decreased after MP-TSCPC treatment to 34.7% (26/75), 26.7% (20/75), 27.8% (20/72), 30.0% (21/70), 30.8% (20/65), 30.0% (18/60), and 27.7% (13/47) at post-operative week 1, months 1, 3, 6, 9, 12, and 15, respectively (Table 2).

**Success Rate, Retreatment, and Complications**

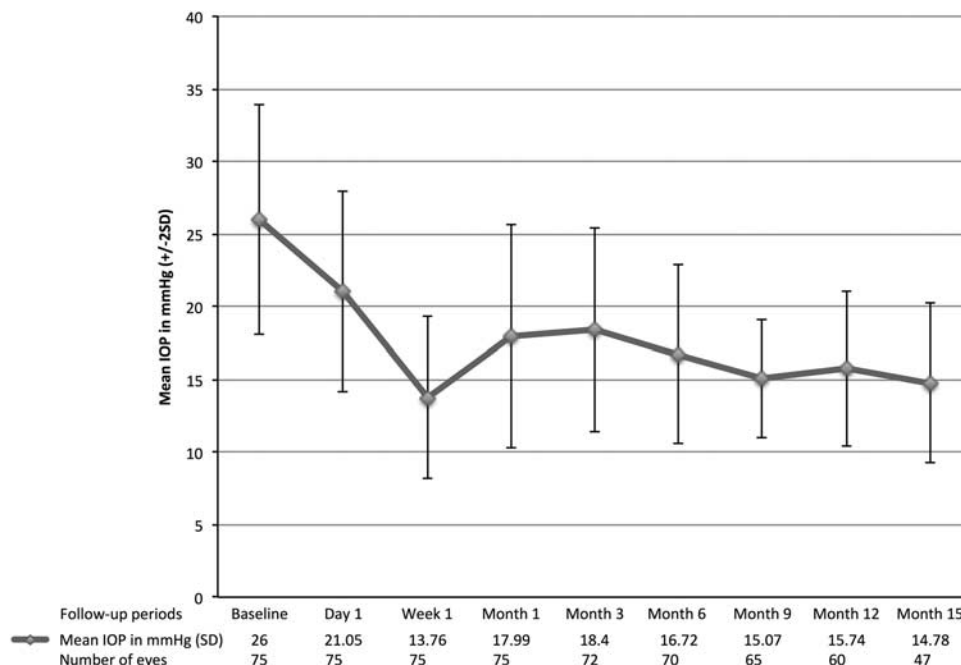
The success rate decreased progressively with time reaching 81.4% at 6 months, 73.3% at 1 year, and 66.0% at 15 months. Up to the 15-month follow-up, a total of 16 eyes of 14 patients (21%) needed additional treatment to control IOP. Six eyes (8.0%) needed a retreatment session with MP-TSCPC (2 eyes at the 6-month follow-up, 3 eyes at the 9-month follow-up, and 1 eye at the 12-month follow-up). Three eyes (4%) needed conventional diode therapy at the 3-, 6-, and 12-month follow-up. Seven eyes (9%) had to undergo glaucoma surgery (Ahmed glaucoma valve implantation) with 4 eyes at the 3-month follow-up, 2 eyes at the 9-month, and 1 eye at the 12-month. No serious complications were reported in the follow-up. Twenty-three percent of eyes experienced postoperative inflammation, with a mild to moderate degree of AC reaction at day 1 following MP-TSCPC, which completely resolved with topical steroids in the weeks following the procedure.

No eyes lost vision completely, but a small and significant decrease in CDVA was noted only in the short postoperative period up to the 1-month follow-up, whereas, at the remaining follow-up periods, CDVA remained stable (Table 2). A total of 8 eyes (14.0%) lost ≥ 2 logMAR lines at the 3-month follow-up visit.

TABLE 2. Evaluated Parameters at Consecutive Follow-up Visits

	Preoperative	Day 1	Week 1	Month 1	Month 3	Month 6	Month 9	Month 12	Month 15
No. eyes	75	75	75	75	72	70	65	60	47
Retreatment	0	0	0	0	5	4	5	2	0
Lost to follow-up	0	0	0	0	3	5	10	15	28
IOP [mean (SD)] (mm Hg)	26.01 (7.91)	21.05 (6.92)*	13.76 (5.57)*	17.99 (7.69)*	18.4 (7.05)*	16.72 (6.17)*	15.07 (4.07)*	15.74 (5.32)*	14.78 (5.50)*
Percentage of IOP decrease [%]		15.9	44.0	25.5	23.9	29.3	36.5	31.8	35.4
Percentage of patients with 20% IOP decrease [%]		45.3	86.7	58.7	63.9	67.1	58.5	56.7	51.1
Percentage of procedure success [%]		65.3	92.0	76.0	80.6	81.4	78.5	73.3	66.0
No. drops [mean (SD)]	3.53 (0.68)	0	3.38 (0.96)*	3.24 (1.01)*	3.25 (1.07)*	3.11 (1.13)*	3.16 (1.11)*	3.08 (1.09)*	3.03 (1.31)
No. acetazolamide tablets [mean (SD)]	0.72 (0.73)	0	0.38 (0.64)*	0.29 (0.59)*	0.27 (0.48)*	0.27 (0.50)*	0.26 (0.57)*	0.23 (0.57)*	0.15 (0.29)*
CDVA in logMAR (SD)	0.86 (0.66)	0.90 (0.68)*	0.95 (0.65)*	0.95 (0.62)*	0.86 (0.60)	0.87 (0.62)	0.89 (0.62)	0.85 (0.61)	0.75 (0.58)

This table represents the different outcomes reported at different follow-up dates. CDVA indicates corrected distance visual acuity; IOP, intraocular pressure. \*Significant P < 0.05.



**FIGURE 1.** Mean IOP ( $\pm 2SD$ ) progression curve in millimeters of mercury over the consecutive follow-up periods. x-axis represents the different follow-up periods. y-axis represents mean IOP  $\pm 2SD$ . IOP indicates intraocular pressure.

**DISCUSSION**

Continuous-wave TSCPC has often been reserved for patients with advanced glaucoma and limited visual potential or for palliation of painful eyes. As such, it has been used as a last-resort treatment for advanced refractory glaucoma.<sup>10</sup> More recent studies have reported on the safety and efficacy of MP-TSCPC making a potential treatment early in the course of glaucoma even in patients with good visual acuity.<sup>19,20</sup> In our prospective interventional study on patients with moderate to advanced refractory glaucoma, a standardized MP-TSCPC protocol was found to be both effective and safe. Success rates decreased progressively to reach 81.4% at the 6-month follow-up and 73.3% at the 12-month follow-up. Significant decrease in IOP, number of drops, and acetazolamide tablets were reported at variable follow-up periods. No major side effects were noted except for a transient decrease in CDVA.

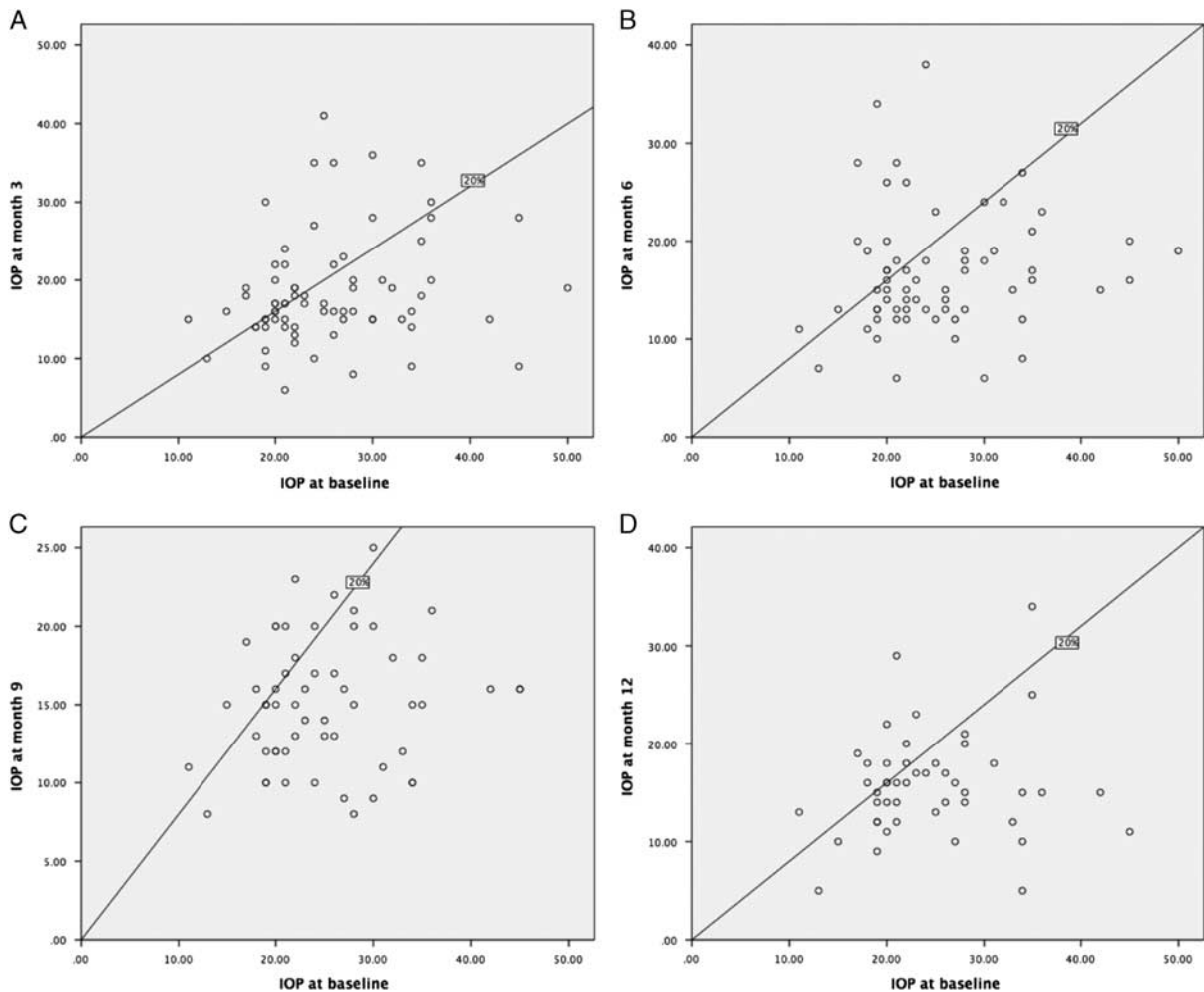
Our success rates were found to be similar to other studies. Williams et al<sup>19</sup> found a success rate (defined as an IOP between 6 and 21 mm Hg or a 20% reduction from baseline) ranging between 66.1% and 74.7%. Aquino et al<sup>11</sup> reported, in their comparative study, a treatment success (defined as IOP between 6 and 21 mm Hg and at least 30% reduction in IOP) in 75% of 24 eyes at the 12-month follow-up.

In our study, IOP showed a significant decrease from baseline with a reduction ranging between 15.9% and 44.0% at different follow-up periods. Tan et al<sup>12</sup> reported an IOP reduction at 1-month follow-up similar to the results found in our cohort (31.7% vs. 25.5% in our study). Emanuel et al,<sup>15</sup> however, reported a higher IOP reduction of 41.2% at the 1-month follow-up but a mean IOP at 1 month compared with our results ( $16.3 \pm 9.5$  vs.  $18.0 \pm 7.7$  in our study).

In addition to IOP reduction, a significant but transient decrease in the need for both topical (from 3.53 to 3.24 at the 1-month follow-up,  $P < 0.001$ ) and systemic treatment

(from 0.72 tablets to 0.29 at the 1-month follow-up,  $P < 0.001$ ) was also noted in our study after MP-TSCPC. Emanuel et al<sup>15</sup> reported a higher decrease in the need for topical eye drops from an average number of drops of 3.3 at baseline to 1.9 at the 1-month follow-up. In other studies, wherein the baseline number of drops needed was lower than what we reported in our study (3.53 drops), the final number of drops needed was also found to be lower.<sup>13,19</sup> However, it is noteworthy that  $> 50\%$  of the patients in our cohort needed acetazolamide tablets at baseline, a treatment that was not used in other studies, except in only 6 patients in the study of Tan et al.<sup>12,15,19,20</sup> At the 9-month follow-up, only 30.8% of patients still needed acetazolamide, with a significant decrease in the number of acetazolamide tablets over all the follow-up periods, which emphasized the efficacy of MP-TSCPC in controlling IOP. This could explain the reason why the number of hypotensive drops did not decrease as drastically as what has been reported in other studies.

No major complications including phthisis or hypotony were reported in our study. A mild but significant decrease in CDVA in the early follow-up associated with a transient postoperative inflammation was only noted up to the 1-month follow-up. Williams et al<sup>19</sup> reported higher complications rates, with 7 patients developing hypotony, 21 patients prolonged AC inflammation for  $\geq 3$  months, 13 patients loss of  $\geq 2$  lines of CDVA for  $\geq 3$  months, and 2 patients phthisis. Similarly, Emmanuel et al<sup>15</sup> reported on 46% of postoperative inflammation at the 3-month follow-up and on a loss of  $> 2$  lines of CDVA in 26.2% of patients. This difference could be due to different patient baseline characteristics or treatment protocol. In our study, we included only white patients. Williams et al<sup>19</sup> and Emanuel et al<sup>15</sup> included, respectively, 30.4% and 29% of African-Americans, which could account for the higher rate of postoperative inflammation reported and other complications in those studies. In fact, there is an association of the nonwhite



**FIGURE 2.** A, Scatter plot comparing IOP in millimeters of mercury at baseline to IOP at the 3-month follow-up. B, Scatter plot comparing IOP in millimeters of mercury at baseline to IOP at 6-month follow-up. C, Scatter plot comparing IOP in millimeters of mercury at baseline to IOP at the 9-month follow-up. D, Scatter plot comparing IOP in millimeters of mercury at baseline to IOP at the 12-month follow-up. x-axis represents baseline IOP, and y-axis represents IOP at respective follow-up periods. Eyes on or below the cutoff line had a decrease in IOP of at least 20% and were considered as a success. IOP indicates intraocular pressure.

ences with a higher incidence of prolonged inflammation and hypotony, resulting in a decrease in CDVA after diode cyclophotocoagulation and other glaucoma surgeries.<sup>19,22–24</sup> Furthermore, studies showing higher complication rates after MP-TSCPC used more intense treatment protocols. Emanuel et al<sup>15</sup> and Williams et al<sup>19</sup> used MP-TSCPC for a mean duration of 300 and 319 seconds, respectively.

Several treatment parameters have been reported in the literature, but this, to our knowledge, is the largest cohort of patients having undergone MP-TSCPC using a standardized protocol with fixed laser parameters: a preset power of 2000 mW, a duty cycle of 31.33% (micropulse “on” 0.5 ms, micropulse “off” 1.1 ms), and a treating time of 180 seconds for each patient. Williams and colleagues and Emmanuel and colleagues used a nonstandardized treatment protocol wherein the treatment parameters were not the same for all patients. Williams et al<sup>19</sup> applied an average treatment time of 300 seconds (range of 120 to 360) in their study. Emmanuel et al,<sup>15</sup> reported an average treatment time of 319 seconds, ranging between 180 and 360 seconds. Both studies reported a higher decrease of IOP compared with our results but with higher

complication rates. In contrast, Tan et al<sup>12</sup> and Aquino et al<sup>11</sup> applied shorter treatment regimens in their reports (100 s per patient), and they obtained similar IOP results and complications compared with our study population, but both studies included only patients with CDVA of 6 of 60 or less, whereas our study included a broader range of CDVA, with a mean of  $0.86 \pm 0.66$  logMAR (range: 0 to 2.1).

In our series, 31 eyes (41.3%) had prior incisional glaucoma surgery (AGV or trabeculectomy, with 3 of these eyes having undergone both procedures). The success rates of MP-TSCPC in these patients were 80.6% at 6 months and 69.2% at 1 year, which were similar to the rates in eyes without prior glaucoma surgery (44 eyes, 57.7%), with 83.4% at 6 months and 77.5% at 1 year ( $P=0.76$  and  $0.42$ , respectively). MP-TSCPC can thus be a viable option in patients with prior failed filtering surgery, given the fact that repetition of incisional glaucoma procedures can be technically demanding and fraught with complications, not to mention the lower success rates of glaucoma reoperations.

Limitations of our study include its moderate sample size and incomplete data at each follow-up interval. Because

of the fact that our hospital at which this study was undertaken is a tertiary care referral center, many patients were followed-up locally for at least some of the postoperative visits.

In summary, the high success rates found until 15 months of follow-up, as well as the absence of serious complications, confirm the safety and effectiveness of this novel noninvasive technique. Although our series is the largest using a fixed treatment protocol studied so far, it is important to note that the number of patients decreased considerably with longer follow-up. Therefore, we believe that more eyes need to be followed-up for longer periods of time in order to better validate our conclusions. Further studies are needed to determine the optimal laser parameters that can provide the best safety and efficacy.

## REFERENCES

1. Quigley HA, Broman AT. The number of people with glaucoma worldwide in 2010 and 2020. *Br J Ophthalmol*. 2006;90:262–267.
2. Weinreb RN, Aung T, Medeiros FA. The pathophysiology and treatment of glaucoma: a review. *JAMA*. 2014;311:1901–1911.
3. Frezzotti P, Mittica V, Martone G, et al. Longterm follow-up of diode laser transscleral cyclophotocoagulation in the treatment of refractory glaucoma. *Acta Ophthalmol (Copenh)*. 2010;88:150–155.
4. Grueb M, Rohrbach JM, Bartz-Schmidt KU, et al. Transscleral diode laser cyclophotocoagulation as primary and secondary surgical treatment in primary open-angle and pseudoexfoliative glaucoma. Long-term clinical outcomes. *Graefes Arch Clin Exp Ophthalmol*. 2006;244:1293–1299.
5. Čanadanović V, Tušek-Lješević L, Miljković A, et al. Effect of diode laser cyclophotocoagulation in treatment of patients with refractory glaucoma. *Vojnosanit Pregl*. 2015;72:16–20.
6. Ramli N, Htoon HM, Ho CL, et al. Risk factors for hypotony after transscleral diode cyclophotocoagulation. *J Glaucoma*. 2012;21:169–173.
7. Murphy CC, Burnett CA, Spry PG, et al. A two centre study of the dose-response relation for transscleral diode laser cyclophotocoagulation in refractory glaucoma. *Br J Ophthalmol*. 2003;87:1252–1257.
8. Osman EA, Al-Muammar A, Mousa A, et al. Controlled cyclophotocoagulation with diode laser in refractory glaucoma and long term follow up at King Abdulaziz University Hospital, Riyadh. *Saudi J Ophthalmol Off J Saudi Ophthalmol Soc*. 2010;24:9–13.
9. Ansari E, Gandhewar J. Long-term efficacy and visual acuity following transscleral diode laser photocoagulation in cases of refractory and non-refractory glaucoma. *Eye Lond Engl*. 2007;21:936–940.
10. Pastor SA, Singh K, Lee DA, et al. Cyclophotocoagulation: a report by the American Academy of Ophthalmology. *Ophthalmology*. 2001;108:2130–2138.
11. Aquino MCD, Barton K, Tan AMWT, et al. Micropulse versus continuous wave transscleral diode cyclophotocoagulation in refractory glaucoma: a randomized exploratory study. *Clin Experiment Ophthalmol*. 2015;43:40–46.
12. Tan AM, Chockalingam M, Aquino MC, et al. Micropulse transscleral diode laser cyclophotocoagulation in the treatment of refractory glaucoma. *Clin Exp Ophthalmol*. 2010;38:266–272.
13. Kuchar S, Moster MR, Reamer CB, et al. Treatment outcomes of micropulse transscleral cyclophotocoagulation in advanced glaucoma. *Lasers Med Sci*. 2016;31:393–396.
14. Lee JH, Shi Y, Amoozgar B, et al. Outcome of micropulse laser transscleral cyclophotocoagulation on pediatric versus adult glaucoma patients. *J Glaucoma*. 2017;26:936–939.
15. Emanuel ME, Grover DS, Fellman RL, et al. Micropulse cyclophotocoagulation: initial results in refractory glaucoma. *J Glaucoma*. 2017;26:726–729.
16. Amoozgar B, Phan EN, Lin SC, et al. Update on ciliary body laser procedures. *Curr Opin Ophthalmol*. 2017;28:181–186.
17. Pantcheva MB, Kahook MY, Schuman JS, et al. Comparison of acute structural and histopathological changes of the porcine ciliary processes after endoscopic cyclophotocoagulation and transscleral cyclophotocoagulation. *Clin Experiment Ophthalmol*. 2007;35:270–274.
18. Way AL, Nischal KK. High-frequency ultrasound-guided transscleral diode laser cyclophotocoagulation. *Br J Ophthalmol*. 2014;98:992–994.
19. Williams AL, Moster MR, Rahmatnejad K, et al. Clinical efficacy and safety profile of micropulse transscleral cyclophotocoagulation in refractory glaucoma. *J Glaucoma*. 2018;27:445–449.
20. Toyos MM, Toyos R. Clinical outcomes of micropulsed transscleral cyclophotocoagulation in moderate to severe glaucoma. *J Clin Exp Ophthalmol*. 2016;7:620.
21. Jabs DA, Nussenblatt RB, Rosenbaum JT. Standardization of Uveitis Nomenclature (SUN) Working Group. Standardization of uveitis nomenclature for reporting clinical data. Results of the First International Workshop. *Am J Ophthalmol*. 2005;140:509–516.
22. Taubenslag KJ, Kammer JA. Outcomes disparities between black and white populations in the surgical management of glaucoma. *Semin Ophthalmol*. 2016;31:385–393.
23. Broadway DC, Chang LP. Trabeculectomy, risk factors for failure and the preoperative state of the conjunctiva. *J Glaucoma*. 2001;10:237–249.
24. Youn J, Cox TA, Allingham RR, et al. Factors associated with visual acuity loss after noncontact transscleral Nd: YAG cyclophotocoagulation. *J Glaucoma*. 1996;5:390–394.